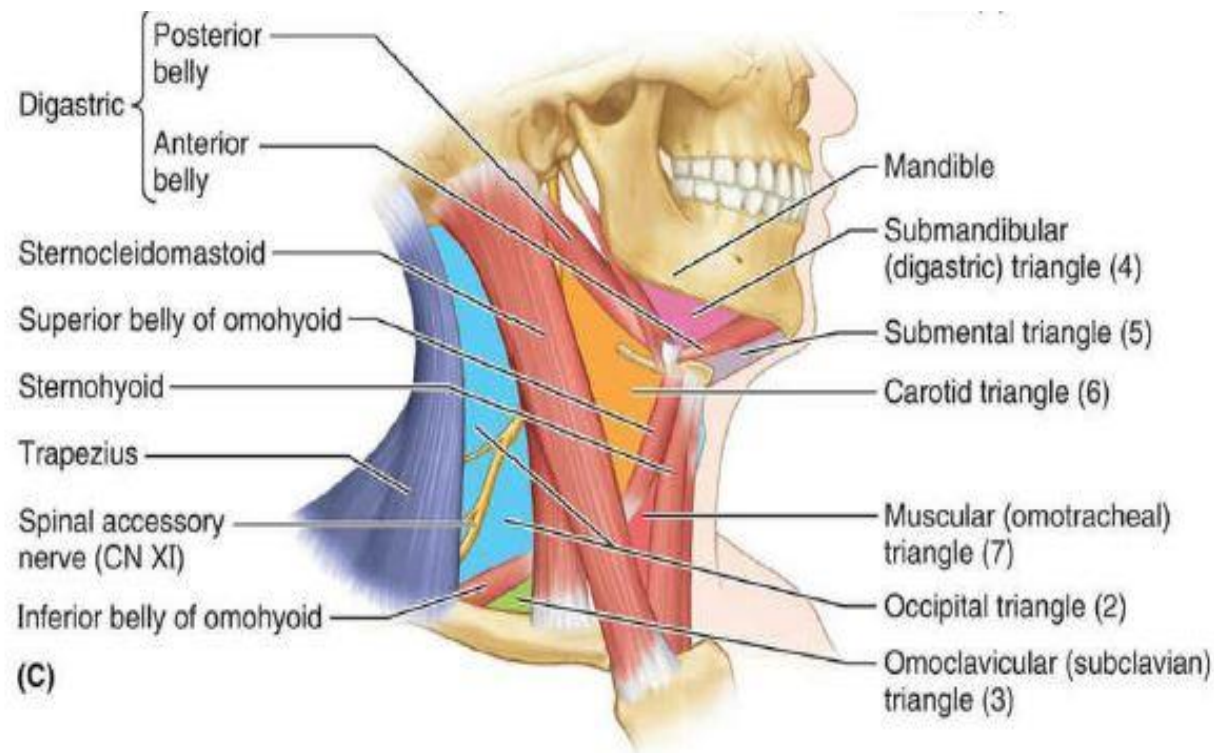
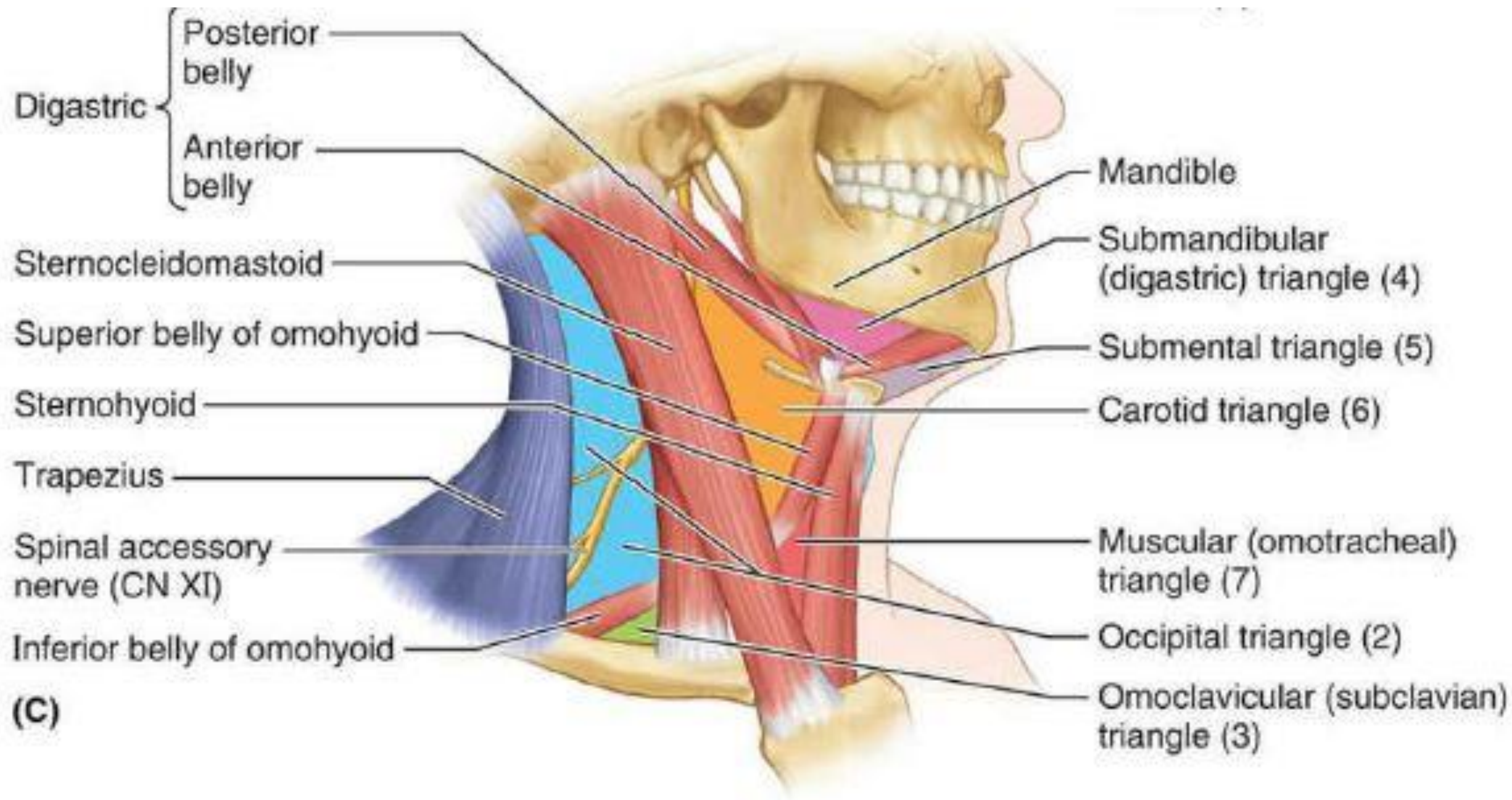


Carotid triangle

Carotid triangle contents

- The carotid triangle is a space at the anterior portion of the neck region and carotid triangle contents following structure including; (@ VANCaL)
 - Veins
 - Arteries
 - Nerves
 - Carotid sheath and its contents
 - Lymph nodes

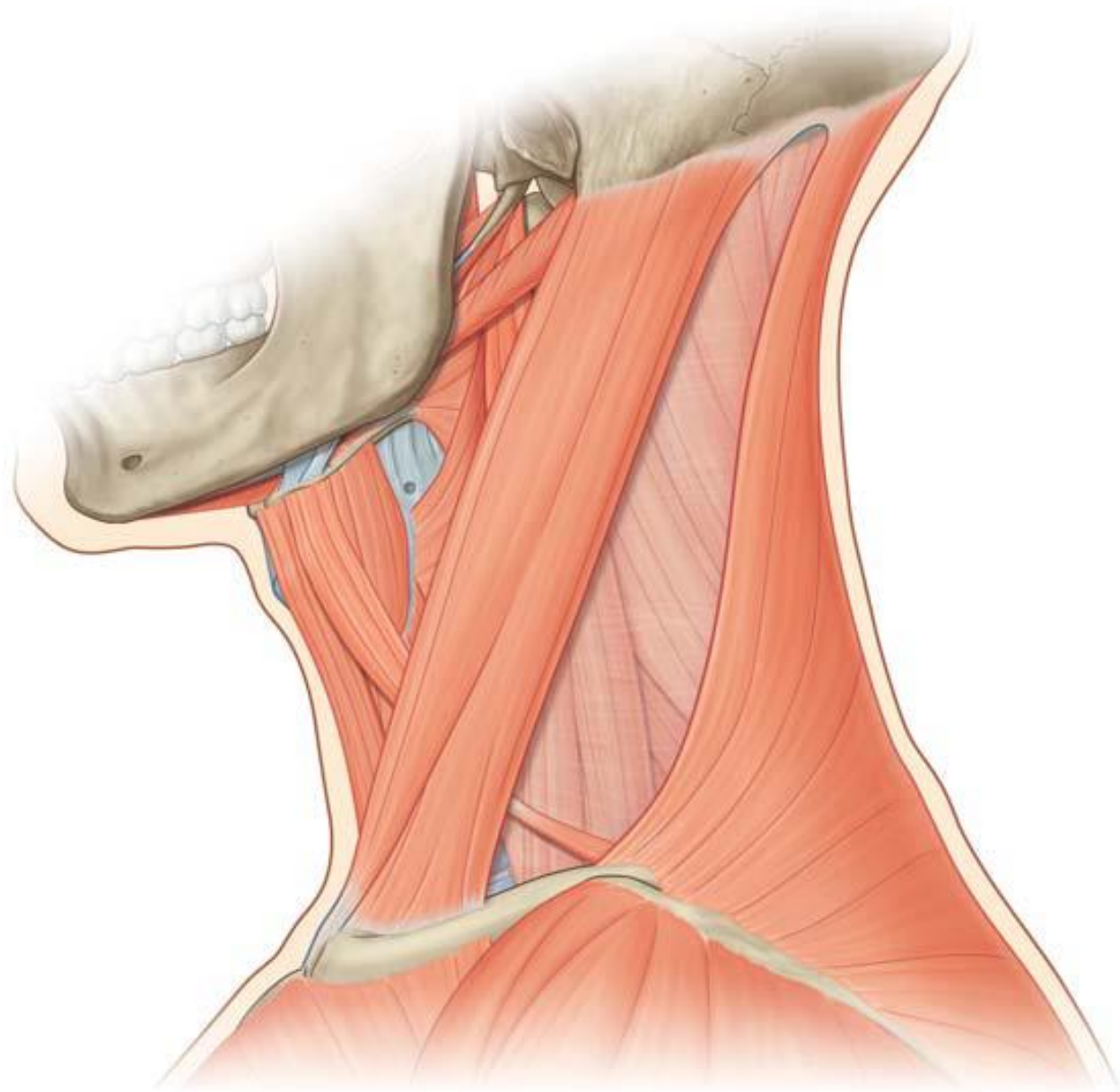




(C)

Carotid triangle contents

- Veins: including following (@ LiP FIj)
 - **L**ingual vein which usually terminates in internal jugular veins
 - **P**haryngeal vein which usually ends in internal jugular veins
 - Common **F**acial vein draining into internal jugular vein
 - **I**nternal **j**ugular vein
- Arteries: including following (@ 3C with its branches)
 - Common carotid artery with carotid sinus and carotid body at its termination
 - Internal carotid artery
 - External carotid artery with its branches such as superior thyroid, lingual, facial, ascending pharyngeal, and occipital arteries

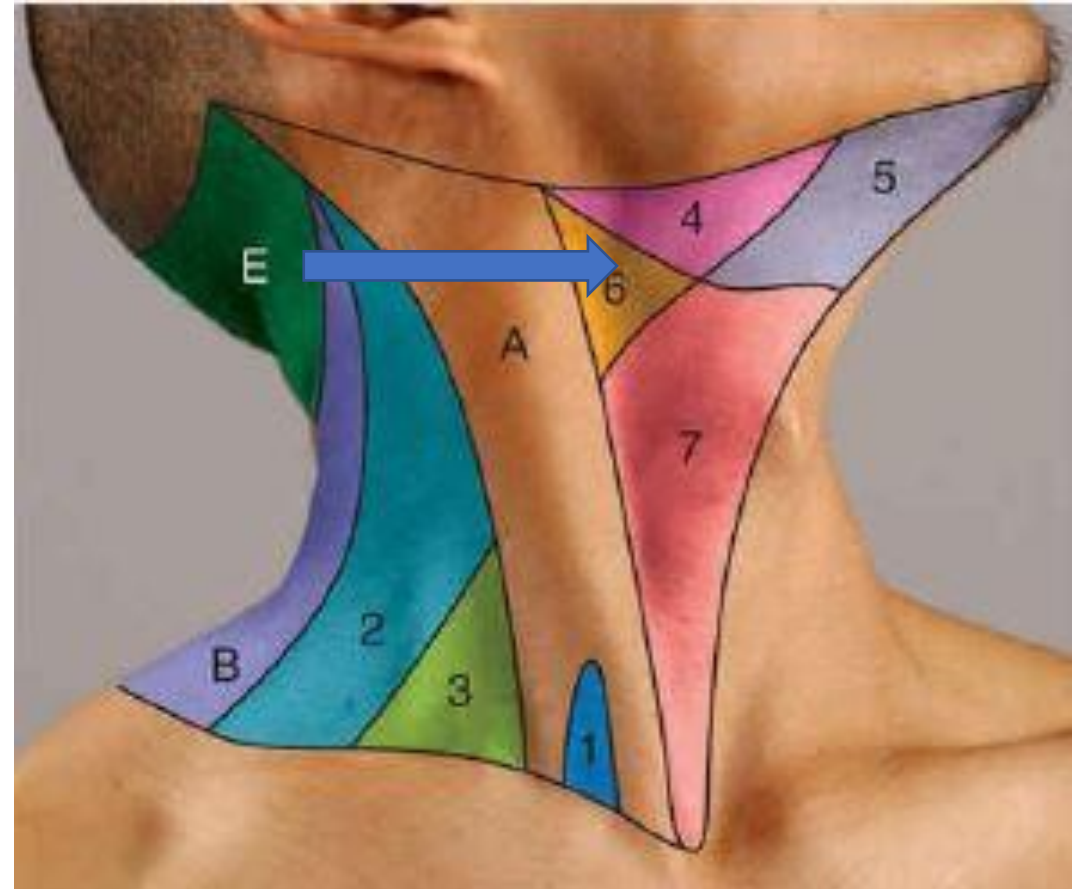


Carotid triangle contents

- Nerves: Including the following (@ VAL HS)
 - **Vagus nerve** running vertically downwards
 - Spinal accessory nerve running backwards over the internal jugular vein
 - Superior laryngeal branch of vagus, dividing into external and internal laryngeal nerves.
 - Hypoglossal nerve running forwards over the external and internal carotid arteries
 - Sympathetic chain running vertically downwards posterior to carotid sheath
- Carotid sheath with its contents such as internal jugular vein, common carotid artery, vagus nerve.
- Lymph nodes: Deep cervical lymph nodes
-

Boundaries of carotid triangle

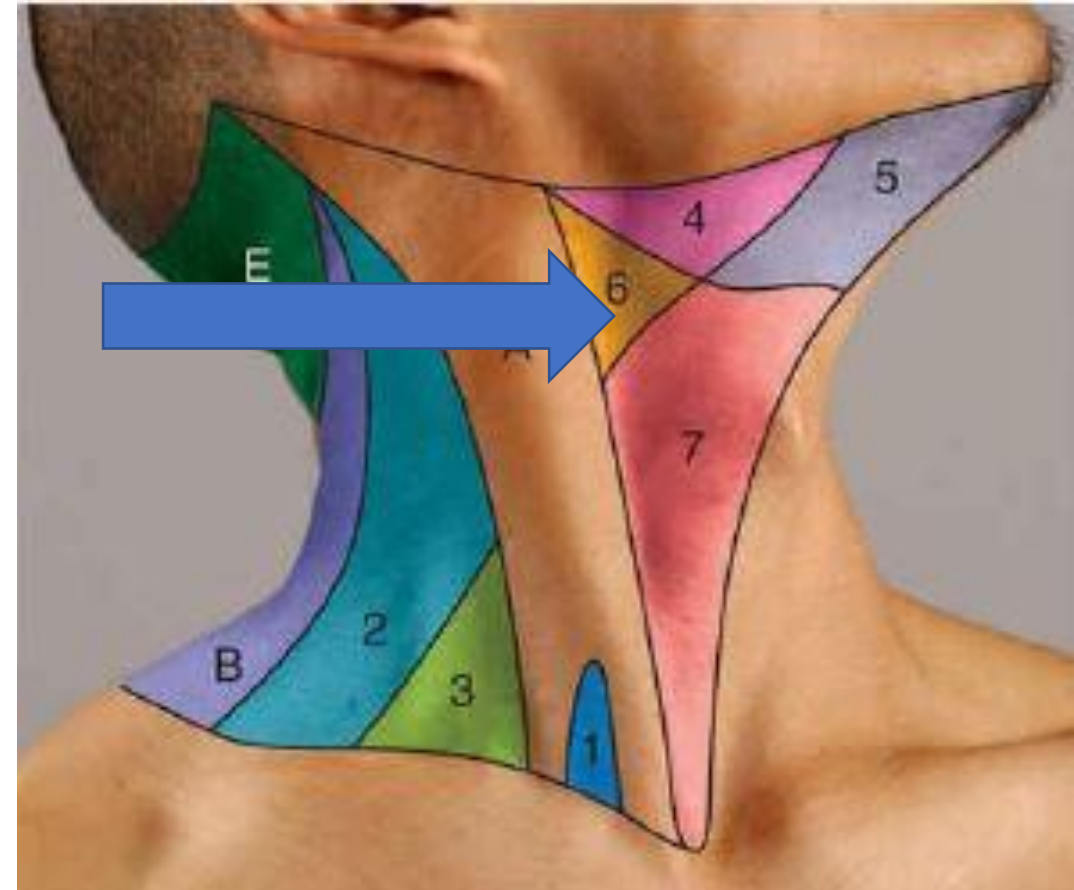
- The boundaries of carotid triangle is following;
 - Anterosuperiorly: posterior belly of digastric muscle, stylohyoid muscle.
 - Anteroinferiorly: superior belly of omohyoid muscle
 - Posteriorly: anterior border of sternocleidomastoid muscle



Boundaries of carotid triangle

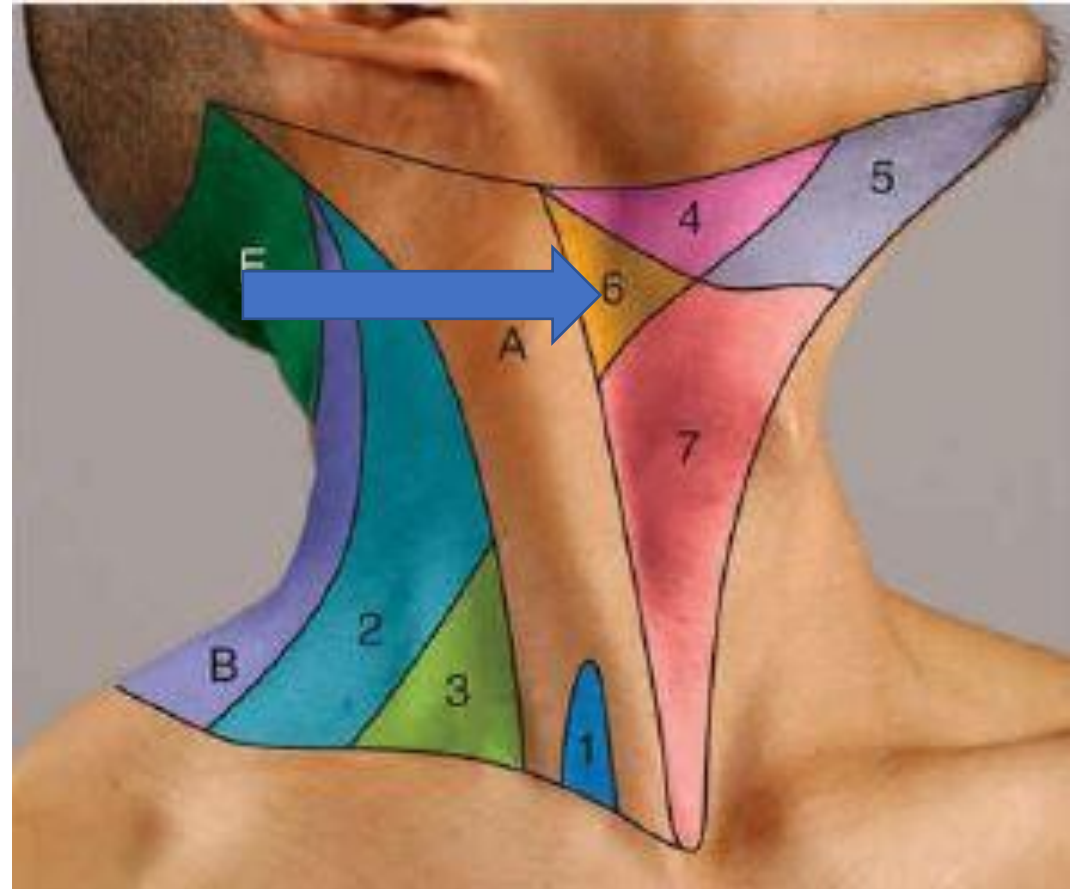
- **Roof**

- The carotid triangle roof contents following structures;
 - Skin
 - Superficial fascia containing
 - Platysma
 - Cervical branch of facial nerve
 - Transverse cutaneous nerve of neck
 - Investing layer of deep cervical fascia



Boundaries of carotid triangle

- Floor
 - The floor of carotid triangle formed by the following structures;
 - Middle constrictor of pharynx
 - Inferior constrictor of pharynx
 - Thyrohyoid membrane



Applied anatomy

- **Carotid sinus syndrome:**
 - The carotid sinus is richly supplied by nerve. In some conditions, the sinus may be hypersensitive and sudden rotation of the head may cause slowing of the heart. This condition is called carotid sinus syndrome.
- **Supraventricular tachycardia:**
 - It may be controlled by carotid sinus massage due to inhibitory effects of vagus nerve on heart.